



International Journal of Fisheries and Aquatic Studies

E-ISSN: 2347-5129

P-ISSN: 2394-0506

(ICV-Poland) Impact Value: 5.62

(GIF) Impact Factor: 0.549

IJFAS 2019; 7(2): 279-281

© 2019 IJFAS

www.fisheriesjournal.com

Received: 14-01-2019

Accepted: 18-02-2019

Swati Jadhav

Department of Zoology,
College, Osmanabad
Maharashtra, India

Atul Humbe

Department of Zoology,
SGRC, Shinde College, Paranda,
Dist Osmanabad, Maharashtra,
India

Nitin Padwal

Department of Zoology,
S.P. College, Bhoom Dist
Osmanabad, Maharashtra, India

Histopathological changes of the intestine of the freshwater fish, *Channa gachua* (Hamilton, 1822) due to infection of metacercaria of trematode parasites

Swati Jadhav, Atul Humbe and Nitin Padwal

Abstract

Channa gachua (HAMILTON, 1822) (Family: Channidae) are considered to be the most delicious fish, is one of the fish that are naturally available and abundant in nature. The metacercariae of *Azygia angusticauda* (Stafford, 1904) Bhalerao, 1942 are found infesting the intestine of these fishes tremendous. During present studies, the four layers of the intestine namely; serosa, muscularis layer, submucosa and mucosa were found severely affected. In T.S. of intestine of *Channa gachua* (HAMILTON, 1822), it has been observed that the *Azygia angusticauda* (Stafford, 1904) Bhalerao, 1942 slowly damage to the intestinal villi, serosa layers, vacuolization in tunica muscularis and lamina propria which indicate that trematodes highly destruct to the host intestine.

Keywords: histopathology, *Channa gachua* (HAMILTON, 1822), intestine

Introduction

Pisces represent a major group of organisms which serve as hosts for many parasites including metacercariae [7]. Parasites are one of the chief causes of mass mortality in fish populations [15, 16]. Parasites when make contact with a host at cellular level, the host reacts bringing into cellular and serological reaction, which is an inflammatory reaction. It is thought that the host is able to distinguish between self and non-self-material, it is not clear as to how these recognition is carried out at genetic level. With the increasing interests in aquatic parasitic infections are becoming threats for fish health management and aquatic crop production throughout the world. Adult fluke invades different organs such as gills, digestive tract, liver and kidney. Earlier studies have been made on the trematode parasite found in the fish [1-6, 14, 15, 19, 22]. It is therefore a vital area for proper pay attention to be given by the scientists for sustainable aquaculture production. Freshwater *Channa gachua* of the family Channidae inhabit a good number of metazoan parasites. Metacercarial infections particularly of *Azygia angusticauda* (Stafford, 1904) Bhalerao, 1942 are heavy in these fishes since they act as intermediate hosts for these digenetic trematodes. If a human accidentally consumes the raw or semi cooked fish, the fluke attaches to human esophagus and causes injury. Parasites effects major pathogenic effects on fish result from hemorrhaging and thickening of the swim bladder wall. They may cause tissue damage and impaired respiration and signs of stress [8], this way cause economic loss. Helminth parasites (Cestodes, trematode, nematode) developed the organs of attachment and antienzyme mechanism for their survival in the body of host. They live in a very hazardous environment, as there is continuous movement of the gut lining, the food present in gut, peristaltic movement and the food material is propelled further down in gut and they are exposed to the gastric and other digestive secretions ingest nutrition by digesting the intestinal content and partially by damaging the intestinal wall with the help of their proteolytic enzymes with their protease inhibitors [11, 12] supposed that proteolytic enzymes or other lytic secretion played a role in pronounced tissue reaction. The physiological Characters may provide favourable or unfavourable site for metabolism of particular species. The nature of diet of the host have profound effect on the growth of helminth parasites, may be lacking in nutritional factor, essential for the development of parasite. This work is an attempt to bring out the different aspect of pathology of infection of fresh water fish *Channa gachua* (Hamilton, 1822), by trematode, *Azygia angusticauda* (Stafford, 1904) Bhalerao, 1942.

Correspondence

Swati Jadhav

Department of Zoology,
R. P. College, Osmanabad,
Maharashtra, India

Materials and Methods

For the histopathological study, the freshwater fish, *Channa gachua* (HAMILTON, 1822), were collected from Sina Kolegoan Dam (M.S.), India and brought to the laboratory and killed by pithing brain they were examination externally (i.e. scale, gills and fins) and later cut opened the fish and observed internally taken out the intestine, liver, heart, spleen in the normal saline water in petridish and cut opened; examination carefully for parasites. The trematode parasite were collected from the intestine, identified worm were kept separately and wash in saline water solution, flattened by using cover glass and slide then preserved in 4% formalin for taxonomical studies. The slides were prepared by Harri's Haematoxyline stain, dehydrated in alcoholic grades (30, 50, 70, 90 and 100%), cleared in Xylene and mounted in DPX. Drawing were made with the aid of Camera Lucida, all measurement are taken in millimeter, identification was carries out by the using Systema Helminthum trematode Vol-I and II (1971) by Yamaguti. The infected intestine attached with the trematode parasite and were kept intact and small pieces of suchintestine were fixed in Bouins fluid for histopathological studied. The fixed tissues were washed in distilled water, dehydrated in alcoholic grades, cleared in xylene, embedded in paraffin wax with melting point (58–60°C). Block was cut at 8 µm and slides were stained with Haematoxyline counter stained with eosin stain. Best slides were selected, observed under the microscope and photographs were taken.

Results

In the present study on closer observation it was found that the metacercariae of trematode *Azygia angusticauda* (Stafford, 1904) Bhalerao, 1942 adhere to the intestine of host fishes. These metacercariae were found attached in cluster to intestine as a white spongy ball in *Channa gachua* (HAMILTON, 1822). The pathological changes were noted in the infected intestine when compared to the uninfected one (Fig.1, 2).



Fig 1: TS. of Normal Intestine of *Channa gachua*

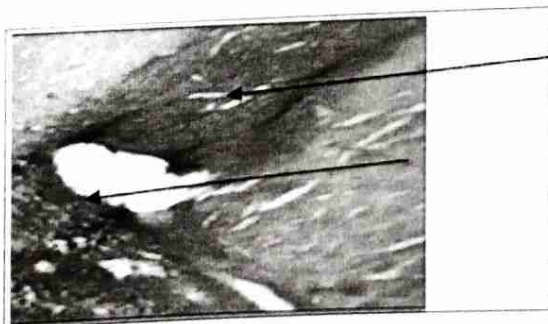


Fig 2: T.S. of Infected Intestine of *Channa gachua* showing degeneration of villi, hyperplasia




Fig 3: T.S. of Infected Intestine of *Channa gachua* showing thick circular muscle layer and the external longitudinal muscle

The pathological effect shows degeneration of villi, ruptured serosa layers, swelling, vacuolization in tunica muscularis and lamina propria and irregular shape of villi occurred formation of thick circular and longitudinal layers (Fig.3).

Discussion

Helmimth parasites affect the host physiology by invading and inhabiting almost each and every organ and thus alerting not only the morphology of organ but also severely interrupting the metabolism and nutritive capacity of the host. Pathogenicity of the host involves an interaction between the parasites and the host. The effect of the parasitism on the fish host is of considerable importance because these fish are one of the important delicious food items for man. The pathophysiological studies on trematode infection in the intestine of fishes have been studied by Benarjee *et al.* [15]. Many studies have been made on the trematodes in fish, relatively few have been concerned with the histopathological changes. The histopathology of *Channa gachua* (Ham) infected by the digenetic trematode *Genarchopsis goppo* has been studied by Bose *et al.* [4]. Pathological changes in cyprinid fry infected by *Bucephallus polymorphus* and *Rhipidocotyle illensis* were found in all the organs of fish by Barbara [12]. Lester *et al.* [10] studied the host-parasite relations in some didymozoid parasites. Muzzal [14] studied the host-parasite relationships of a trematode *Triganodistomum attenuatum* infecting the white sucker. Chung-yui-tan [22] studied the histopathology in the Wolfian ducts of *Hypentelium nigri* caused by a trematode *Phyllodistomum superbum*. Maqbool *et al.* [13] studied the histochemical and histoenzymological studies on the metacercariae of *Clinostomum complanatum*. A digenetic trematode *Orienticreadium batrachii* was found to be is one of the dominant parasites infecting the host species of cat fishes reported by Zarina *et al.* [23].

The histopathology causes the intestine of infected fish which is significantly showing the extensive damage to the four layers i.e. Mucosa, Submucosa, Muscularis, and Adventia layer. The intestine consisted of small intestine and large intestine. The small intestine comprised a simple layer of columnar epithelium with prominent microvilli, high degree of villous folding with abundant Goblet cells (Fig. 1). The large intestine lined by a simple columnar epithelium with abundance of Goblet cells compared to the rest of the intestinal segments. The lamina propria consisted of compact connective tissues, with numerous blood vessels especially at the tip of the villi. The pathological effect shows degeneration of villi, ruptured serosa layers, swelling, vacuolization in

tunica muscularis and lamina propria and irregular shape of villi occurred formation of thick circular and longitudinal layers (Fig. 3) This results that, worm contact with host tissue and utilize their nutritive substances for their growth, nourishment and make host weak, affecting the growth of host causing damage to intestinal tissue of host evidenced by eruption of villi, thickening of more intestinal layers. Similar trend was noticed by Banerjee *et al*^[14], Laxma *et al*^[9].

Conclusion

From the present study, it was concluded that *Channa gachua* is highly infected with trematode parasite *Azygia angusticauda* (Stafford, 1904) Bhalerao, 1942 which utilize the nutritive material from host and alters the levels of various metabolites in the body in the resulting the change of metabolic activities and physiological activities of the host. It will be resulted into decreasing economical value or nutritive value of host.

References

1. Alam SM, Nizami WA. Histochemical and histoenzymological studies on the metacercaria of *Clinostomum complanatum* (Trematoda: Digenea) Helminthologia. 1984; 21(1):21-31.
2. Barbara B. Pathological changes in cyprinid fry infected by *Bucephalus polymorphus* and *Rhipido cotyleillensis* metacercariae (Trematoda, Bucephalidae) Act Parasitol Pol. 1980; 27(15-18):241-246.
3. Bhargavi GY, Krishna GVR *et al*. Haematological changes in fresh water fish, *Channa punctatus* (Bloch) infected with metacercariae of progenetic worm *Euclinostomum heterostomum* (Trematoda) Proc Indian Sci Cong Ass Goa (abs). 1993; 80:174-175.
4. Bose Sinha. The histopathology of the stomach wall of the fish *Channa gachua* (Ham) (Channidae) attributable to the digenetic trematode, *Genarchopsis goppo* (Ozaki) Hemuridae. Current science. 1979; 48(16):747-748.
5. Christina S. The pathology of *Haplorchis punilio* infections in cultured tilapias. J Fish Dis. 1982; 3:243-250.
6. Gupta AK, Agarwal SM *et al*. Host-parasite relationships in *Channa punctatus* and *Euclinostomum laterostomium* Curr Sci. 1983, 52(23).
7. Hoffman GL, Dunbar CE *et al*. Synopsis of Strigegeodea (Trematoda) of fishes and their life cycle Fish Bull 175, United states Department of the Interior Fish and Wild life Service Washington. 1967; 60:439-469.
8. Koie M. Swim bladder nematodes (*Anguillicola* spp.) and gill monogeneans (*Pseudodactylogyrus* spp.) parasitic on the European eel (*Anguilla anguilla*). Journal de la Conseil. International pour Exploration de la Mer. 1991; 47:391-398.
9. Laxma Reddy B, Banerjee G *et al*. Histopathology of intestine of trematode helminth infected fish Int. J. Curr. Microbiol. App. Sci. 2014; 3(2):330-334.
10. Lester RJG. Host-parasite relations in some didymozoid trematodes. J Parasitol. 1980; 66(3):527-531.
11. Mitchell AJ. Pathogenicity and histopathology of an unusually intense infection of white grubs (*Posthodiplostimum m. minimum*) in the fished minnow (*Pimephales promelas*) J Wildl Dis. 1982; 18(1):51-57. [PubMed]
12. Mackiewicz JS, Cosgrove GE, Gude WD. *et al*. Relationship of pathology of scolex morphology among caryophylloid cestodes. Zeitschri fur Parasiten kunde. 1972; 39:233-246.
13. Maqbool, Wajiha Alam S, Nizami *et al*. Histochemical and histoenzymological studies on the metacercaria of *Clinostomum complanatum* (Trematoda; Digenea). Helminthology. 1980; 21(1):24-31.
14. Muzzal PM. Population biology and host-parasite relationships of *Triganodistomum attenuatum* (Trematoda: Lissorchiidae) infecting the white sucker, *Catostomus commersoni* (Lacepede) J Parasitol. 1980; 66(2):293-298.
15. Orecka - Grabda T. Haemato and histopathological changes in the whitfish (*Coregonus* Linn) invaded by metacercariae of *Cotylurus erraticus* (*Synlthyocotylurus*) (Rudolphi, 1809). Fish pathology: 1991; 22:13-19.
16. Paperna I, Vanas J *et al*. The pathology of *Chilodenella hexastica* infections in cichlid fishes. Journal of Fish Biology. 1983; 23(4):441-450.
17. Pardeshi P, Hiware C, Wangaswad C. *et al*. Histopathology of Liver of *Masatcembelus armatrus* (Lacepede, 2008) due to trematode parasite, *Allocreadium* Kham n. sp. Journal of Parasitology Disease. 2012; 36(1):53-55.
18. Reddy B, Lakshma G, Banerjee G, Rajender V, Bikshapathi M, Rama Rao NJ *et al*. Histopathology and histo chemical abnormalities induced by *Euclinostomum heterostomum* in the liver of freshwater fish, *Channa punctatus*. J Aqua Biol. 2006; 21(2):263-267.
19. Sinha AK, Sinha C, Nikhil R *et al*. Studies on yellow grub disease of freshwater fish, *Channa punctatus* (Bloch). Curr Sci. 1988; 57(4).
20. Valtonen ET, Haparanta A, Hoffmann R *et al*. Occurrence and histological response of *Raphid ascarisacus* (Nematoda-Ascaridoidea) in roach from four lakes differing in water quality. Int J Parasit. 1994; 24:197-206. Doi: 10.1016/0020-7519(94)90026-4. [PubMed] [Cross Ref].
21. Yamaguti S. A synopsis of digenetic trematodes of vertebrates. Tokyo: Keigaku Publishing Co. Ltd. 1971, 1, 2.
22. Y-tan Chung. A study on the histopathology in the walfian ducts of *Hypentelium nigricans* (Osteichthyes: catostomidae) caused by *Phyllodistomum superbum*. QJ Taiwanmus (Taipei). 1981; 34(3/4):237-240.
23. Zarina Z. Infections of digenean trematode. *Orientocreadium batrochii* in two specis of genus *Clarias* collected from Kedahh state of Malasia, Dhaka Uni. stud. Part, E. Biol. Sci. 1990; 5(2):105-114.



Sud

PRINCIPAL
S.P. Mahavidyalaya, Bhoom
Dist. Osmanabad